



AIMS

To carry out a cadaveric study on the anatomical variation of the Flexor Digitorum Profundus (FDP) muscle, with focus on the average position of the proximal tenomuscular junction (PTMJ), which can be used to determine the extent of deep forearm laceration injuries.

BACKGROUND

Deep laceration injuries of the forearm will most likely involve the FDP however, surgical management may vary depending on whether the tendinous or muscular portion has been affected⁴. This can be differentiated at PTMJ, the location of which varies between the four FDP tendons. Thus, having an understanding of the average position of the PTMJ can allow surgeons to determine the location, management and overall prognosis of the injury. Due to COVID-19, we are unable to provide cadaveric photographs as of yet, nevertheless, digital images have thus been used to illustrate the PTMJ⁵ (right).

METHODS

Four fresh frozen cadaveric forearms were dissected to study the underlying anatomy and biomechanical arrangement of the FDP. First, the total apparent length of the FDP was measured from the medial epicondyle (ME) of the humerus to the proximal mouth of the carpal tunnel (PMCT). Secondly, from the ME, the PTMJ was then identified as the most proximal point at which tendon and muscle began to merge. Biomechanical excursion of the FDP tendons was also obtained in this study.

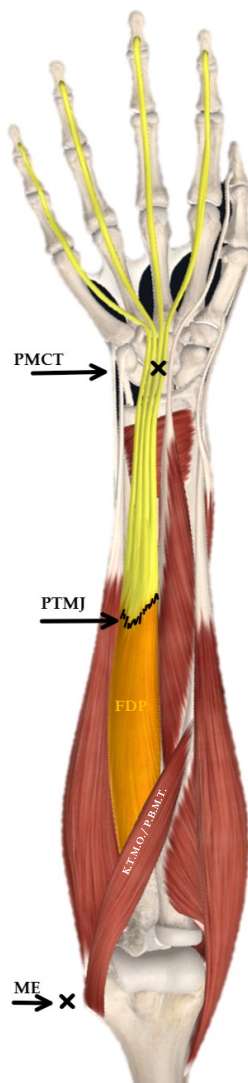


Fig. 1(Above): FDP and position of the PTMJ.

RESULTS

The mean apparent FDP length equalled 242.8 ± 2.42 mm and the mean position of the PTMJ for the 2nd, 3rd, 4th and 5th FDP tendons are as follows: 96.6 ± 11.4 ; 98.2 ± 6.01 ; 102.7 ± 8.2 and 84.6 ± 21.1 mm, respectively. The PTMJ was represented as a percentage of the mean apparent FDP length; as follows (%): 39.8; 40.4; 42.3 and 34.8, respectively (below). Thus, the average PTMJ was found to be present at approximately 39.2% (or 2/5) of the apparent FDP length.

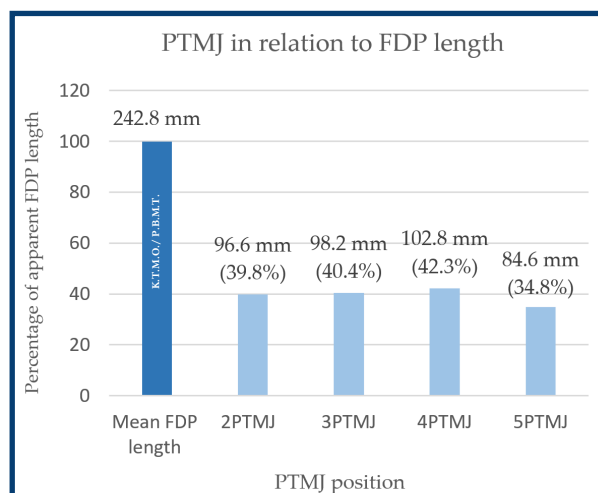


Fig. 2(Above): Bar chart illustrating the PTMJ of each FDP tendon as a percentage of the mean apparent FDP length (ME to PMCT).

CONCLUSION

Upon examination of a suspected deep forearm laceration injury, the position of the PTMJ can be estimated to be present at the proximal 2/5 of the patient's forearm. Whether the tendinous or muscular portion of the FDP is likely to be damaged, can be determined by whether the injury is present proximal or distal to the approximate position of the PTMJ.

REFERENCES

- 1) Schreuders, T. (2011). The Quadriga phenomenon: a review and clinical relevance. *Journal of Hand Surgery (European Volume)*; 37(6), pp. 513-522.
- 2) Tubiana, R., Thomine, J., Mackin, E. (1996). *Examination of the hand and wrist*. New York: Informa Healthcare USA Inc.
- 3) Verdan, C. E. (1960). Syndrome of the Quadriga. *Surgical Clinics of North America*; 40(2), pp. 425-426.
- 4) Warwick, D., Dunn, R., Melikyan, E. and Vadher, J. (2009). *Hand Surgery (Oxford Specialist Handbooks in Surgery)*. Oxford University Press.
- 5) 3d4medical.com. (2020). Complete Anatomy 2020 | Complete Anatomy. [online] Available at: <https://3d4medical.com/press-category/complete-anatomy> [Accessed 12 June 2020].